

SMALLPOX - CLINICAL AND LABORATORY DIAGNOSIS

	<u>Page</u>
1. Clinical smallpox	II-2
1.1 Variola major	II-2
1.1.1 Classification of cases	II-2
1.1.2 Haemorrhagic variety	II-2
1.1.3 Flat variety	II-3
1.1.4 Ordinary variety	II-4
1.1.5 Modified variety	II-5
1.1.6 Variola sine eruptione	II-6
1.2 Variola minor	II-6
1.3 Summary of characteristics of the principal varieties . .	II-6
1.4 Frequency of different clinical varieties	II-7
1.5 Differential diagnosis	II-7
1.5.1 Prodromal phase	II-8
1.5.2 Early eruptive stage	II-8
1.5.3 Vesicular and pustular stage	II-9
2. Laboratory diagnosis of smallpox	II-9
2.1 Collection and despatch of specimens	II-10
2.1.1 Collection	II-10
2.1.2 Despatch	II-10
2.1.3 Kit for specimen collection	II-11
2.2 Diagnostic methods	II-12
2.2.1 Virus isolation	II-12
2.2.2 Agar-gel diffusion precipitation method	II-13
2.2.3 Complement-fixation	II-13
2.2.4 Electron microscopy	II-14
2.2.5 Histological examination	II-14
2.2.6 Immunofluorescence	II-15
2.2.7 Serological methods	II-15

SMALLPOX - CLINICAL AND LABORATORY DIAGNOSIS

This section provides a brief synopsis only of the clinical features of smallpox, methods for the collection of specimens and commonly employed procedures for laboratory diagnosis. Subjects as complex as these can, of course, be dealt with only in summary. For a more detailed discussion, attention is directed to the several references cited.

1. Clinical smallpox1.1 Variola major1.1.1 Classification of cases

Several classifications as to types of smallpox have been proposed on the basis of clinical and prognostic features. Dixon ¹, for example, lists nine different types. Rao ², on the basis of extensive clinical experience in Madras, notes five different varieties and a total of 12 subvarieties. Although perhaps useful to the skilled smallpox diagnostician, the multiplicity of types with their many overlapping characteristics is probably more confusing than helpful to the field epidemiologist. Accordingly, in this summary, variola major is discussed from the vantage point of a simplified classification, based on both Dixon's descriptions and Rao's classification.

<u>Clinical variety</u>	<u>Other designations</u>	<u>Approximate Dixon classification</u>
a. Haemorrhagic	Fulminating, purpura variolosa	Type 1
b. Flat	Malignant, confluent or semi-confluent	Types 2, 3
c. Ordinary	Benign confluent, semi-confluent or discrete	Types 4-8
d. Modified	Vaccino-modified	
e. Variola sine eruptione		Type 9

1.1.2 Haemorrhagic variety

Invariably fatal, cases with this form of smallpox are often diagnosed in retrospect unless they occur during the course of a recognized epidemic.

After the customary 12 to 14 day incubation period, the patient becomes acutely, severely ill with headache, backache and a temperature of 101-102°F (38.3-38.9°C). Although appearing apprehensive, he is usually fully conscious although exhausted and withdrawn. The blood film reveals numerous lymphocytes and many myeloblasts. Death sometimes occurs within 24 to 36 hours with no clinical findings and few at autopsy.

If the patient survives more than 48 hours, a dusky erythema appears on the face and back of the hands and a blotchy erythema on the arms and trunk, particularly the anterior abdominal wall and the upper part of the thighs. Temperature continues in the previous range. Haemorrhages or large blood-filled

bullae may sometimes be observed under the mucous membrane of the mouth. Petechiae may become evident in the skin, particularly on the abdomen and upper thighs, which over a 24-hour period rapidly enlarge forming distinct ecchymoses. Haemorrhagic areas subsequently extend to affect much of the body surface. If the patient survives sufficiently long, a slight papular eruption may be noted. Death normally occurs by the fifth or sixth day as the result of a profound viremia-toxemia or massive gastrointestinal or uterine haemorrhage.

In the absence of epidemiological clues suggesting the diagnosis of smallpox, these cases are often misdiagnosed as idiopathic thrombocytopenic purpura, acute leukaemia, etc.

1.1.3 Flat variety

Often termed "malignant" smallpox, the disease is frequently fatal, particularly if the rash is extensive.

The onset is sudden with moderate fever, 101-102°F (38.3-38.9°C), malaise, intense headache, backache and myalgia. The patient is normally anxious but alert. Until a rash develops, the prodrome simulates influenza. Vomiting and abdominal pain may develop on the second or third day suggesting, in some cases, an acute abdominal problem.

After two to three days, symptoms recede to some degree, ~~but within a period of 12 to 14 hours, the fever again rises and a dusky erythema appears on the face and a mixed, irregular petechial and macular eruption on the upper chest, neck, back and arms.~~ ^{and} The rash is pleomorphic in appearance and is generally confined to the upper half of the body.

The erythema over the face, which soon takes on the appearance of a severe sunburn, changes imperceptibly into a diffuse and, in more severe cases, nearly confluent vesiculation with accompanying intracuticular oedema. The appearance is like that of a fine grained reddish-coloured crepe rubber. Close inspection may reveal a few small, thin-roofed vesicles, sometimes with small haemorrhages at their bases. The lesions are soft and evolve slowly. Lesions continue to develop over the first eight days or so involving progressively the forearms and hands, upper legs, lower legs and feet. The usual centrifugal distribution of lesions may or may not be evident.

Lesions also develop on the mucous membranes of the mouth and the palpebral conjunctiva with the subsequent evolution of keratitis, corneal ulceration and sometimes blindness.

By the tenth day of illness, lesions become vesicular but are soft, flattened and velvety, hot and tender to the touch. Local haemorrhage into the skin may occur. Great loss in weight becomes evident. By the twelfth or thirteenth day, if the rash is extensive, large amounts of epidermis begin peeling away, particularly over pressure areas, leaving these areas painfully tender to the touch. Thrombocytopenia, lymphocytosis and neutropenia are usually observed. In fatal cases, death commonly occurs between the eighth and fifteenth day, apparently as a result of overwhelming toxemia or because of haemorrhage. In general, it would appear that the more extensive the rash, the higher the fatality rate.

If the patient survives, the lesions normally do not evolve beyond the vesicular stage, receding without progressing to pustule formation.

The failure of the rash to complete the usual maturational sequence is the characteristic mark of the flat variety.

1.1.4 Ordinary variety

After the usual 12 to 14 day incubation period, the patient experiences a sudden onset of fever, headache, backache and malaise. The temperature is usually somewhat higher ($103-104^{\circ}\text{F}$ or $39.4-40.0^{\circ}\text{C}$) than in the two more malignant types. A fleeting erythematous rash may sometimes be observed over the thighs and groin, especially among those previously vaccinated. After two to four days, there is normally a remission in symptoms and fever.

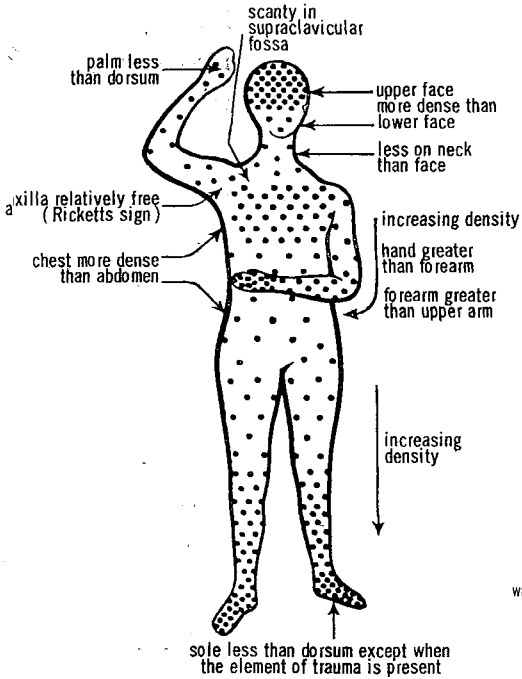
Within a day or so following this prodromal period, the rash begins to develop and, with it, a slight ^{sudden} increase in fever. A few macular spots (herald spots) first develop, usually on the face, over the malar region, bridge of the nose, or over the trachea, with occasional spots on the chest, forearms and back. Within 24 hours, additional lesions appear on the face. The macules rapidly become papules and subsequently vesicles and feel deep and shotty to the touch. This is caused by vacuolation in the epidermis and the formation of fluid under pressure. The rash rapidly spreads to involve the back, arms, chest, hands, legs and feet in that order; lesions ^{usually} may also appear ~~on the hard and soft palate, as well as on the mucosa of the cheeks and tongue.~~

The rash is characteristically centrifugal in distribution with a greater concentration of lesions on the more peripheral parts (see following figure). The density of rash is also usually greater over bony prominences, tendons, points of pressure or mild irritation (e.g. at site of a garter). By the fifth or sixth day of rash, the lesions are pearly white, multi-loculated (when pricked, only part of the vesicle collapses), about 7-10 mm in diameter, deeply set in the skin with a narrow red areola. They are neither tender to the touch nor do they feel hot. As the lesions enlarge, oedema develops in the immediately adjacent and underlying skin. The lesions subsequently become pustular and umbilicated. The pustules, however, do not normally contain pyogenic organisms.

Scabs form and by the fourteenth day begin to come off the face. The scabs take 20 days or more to be shed completely; the process occurs in the same order as the development of the rash, beginning at the head and extending centrifugally. The crusts and "seeds" on the palms and soles usually take a particularly long time to separate.

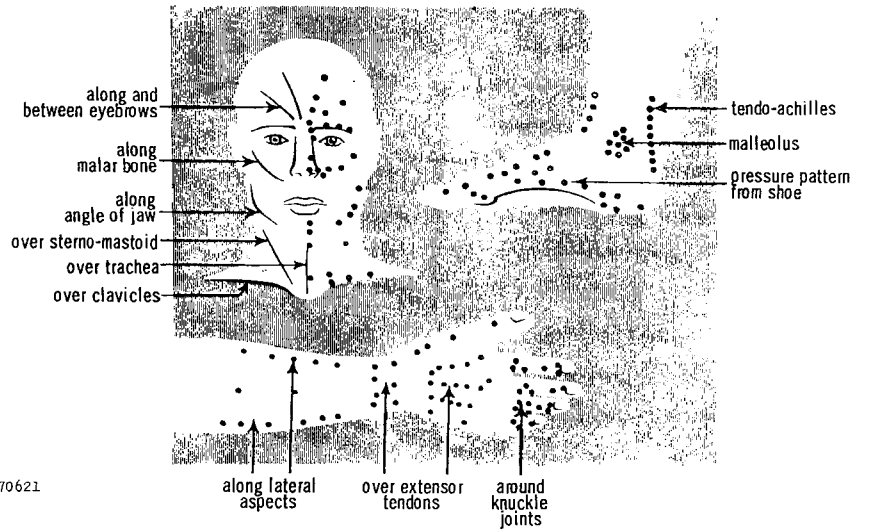
The severity of symptoms at all stages in the evolution of the rash is generally more severe with a more extensive rash. The likelihood of a fatal outcome is similarly greater with a more extensive rash.

NORMAL DISTRIBUTION OF RASH



WHO 70621

SITES OF ELECTION OF RASH



Reproduced by permission from SMALLPOX by C. W. Dixon, London, J. & A. Churchill Ltd.

1.1.5 Modified variety

Previous vaccination may or may not result in a significant modification of the type of rash which is observed. Significant modification of the rash, when it occurs, may cause a diagnostic problem.

Although the characteristic prodrome is usually observed, the lesions are comparatively sparse in number, may appear in "crops" over a period of as much as five to six days, mature much more rapidly and may not progress beyond a papular stage before resolving. In general, lesions still tend to occur in a centrifugal distribution and over pressure points. The lesions are more superficial and, in any given area, may appear to be in several stages of development (not unlike varicella). The usually round, regular lesion normally observed in smallpox may appear, in the modified form, as oval or crenated; early lesions tend to have a rather extensive area of surrounding erythema.

In some instances, diagnosis of such cases is impossible without laboratory assistance.

1.1.6 Variola sine eruptione

In this type, the patient experiences the usual influenza-like prodrome approximately 12 to 14 days after exposure but fails to develop the usual rash. Such cases appear to be rare; from present data it would appear that the individuals do not readily transmit infection to others.

1.2 Variola minor

Although some claim to be able to detect subtle clinical differences between variola major and variola minor, most clinicians are unable to differentiate between individual cases of the two diseases. Although any of the different varieties may be observed, in any series of cases, there are few severe cases and virtually none of the flat and haemorrhagic varieties; patients generally exhibit fewer lesions and, of course, fewer systemic symptoms; deaths are much less frequent.

Most clinicians, presented with a case of the ordinary variety of variola major and one of variola minor with comparable numbers of lesions, are able to detect nothing whatsoever to distinguish one from the other.

1.3 Summary of characteristics of the principal varieties

With respect to the categories presented, emphasis is placed simply on the nature and evolution of the lesions themselves. With the flat, ordinary and modified types, the lesions may be more or less extensive and each of these varieties may be subdivided into confluent, semiconfluent and discrete types. In general, it may be said that the greater the number of lesions, the more severe the illness and the more likely a fatal outcome. Further distinction of each of the varieties in this manner, however, is not particularly helpful for epidemiological or surveillance purposes.

- | | |
|------------------------|---|
| Haemorrhagic | - Haemorrhage proceeds a focal rash; vesicles do not develop before death. |
| Flat | - Rash develops to vesicular stage before patient succumbs or resolution takes place. Haemorrhage may be present but occurs after the development of focal lesions. |
| Ordinary | - Typical smallpox with usual evolution of lesions through macular, papular, vesicular, pustular, scabbing stages. |
| Modified | - As a consequence of prior partial immunity, lesions undergo a more rapid evolutionary course; some or all may be atypical. |
| Variola sine eruptione | - Febrile illness without lesions. |

1.4 Frequency of different clinical varieties

Emphasis has frequently been placed on the difficulty of diagnosis of smallpox cases. Clinicians refer particularly to the haemorrhagic and flat varieties and to modified cases as posing serious diagnostic problems. In certain cases, this concern is quite valid. However, so much emphasis has been placed on the atypical cases of smallpox that many have come to regard the typical case as a comparative rarity. In fact, however, it is the atypical case which is rare rather than the reverse.

Rao² has provided an approximation of the frequency with which the different varieties of variola major were observed over a period of years in Madras.

<u>Clinical variety</u>	<u>Per cent. distribution</u>	
	<u>Vaccinated</u>	<u>Unvaccinated</u>
Haemorrhagic	3	2
Flat	1	7
Ordinary	71	89
Modified	24	2
Variola sine eruptione	< 1	0

It is to be noted that the great majority of cases are of the so-called "ordinary" type which present few difficulties with respect to diagnosis. Next in frequency are the modified types (among vaccinated individuals); although some "modified" cases may be difficult, sometimes impossible, to identify clinically, the majority exhibit reasonably classical features. Clearly more difficult to diagnose are the "flat" varieties although many cases even in this category are reasonably recognizable. The two remaining types, the "haemorrhagic" and the uncommon "variola sine eruptione" are virtually impossible to recognize except during an outbreak and, in the latter case, only with laboratory facilities.

During recent outbreaks in Asia, Africa and South America, 80 per cent. or more of the cases have occurred in unvaccinated persons. At least 90 per cent. of these are typical, readily recognizable, clinical cases. Of the smaller proportion occurring among vaccinated persons, at least 80 per cent. are reasonably typical cases. Over-all, therefore, clinically typical cases account for at least 85 per cent. to 90 per cent. of all cases in an outbreak, the remainder ranging from somewhat atypical to the very difficult diagnostically. This has been the experience in Madras and was similarly the experience during outbreaks which occurred in recent years in comparatively well-vaccinated populations in the United Kingdom and Sweden.

1.5 Differential diagnosis

Of primary importance in the differential diagnosis is the patient's immediate and past history. Has he been in contact with possible cases of smallpox or varicella during the incubation period? A negative history of contact with variola or varicella does not, of course, exclude the diagnosis of either; a positive history does, however, suggest more strongly one diagnosis or the other. Has the patient previously experienced either smallpox or

varicella? Repeat attacks of either illness are rare. Has the patient been vaccinated; does he have a primary scar? Smallpox in a recently well vaccinated individual is comparatively unlikely; on the other hand, vaccination 10 to 12 days previously suggests the possibility of disseminated vaccinia, particularly in an individual undergoing primary vaccination or revaccination after a very long period. Is the patient taking any drugs which might result in a drug rash? Virtually any of the drugs may induce a drug rash which may assume any of a variety of confusing rashes. Has the patient a history of syphilis or contacts which would make the diagnosis of secondary syphilis, for example, a likely possibility?

Surprisingly often such simple questions as these are never explored before examining more closely the clinical illness itself.

1.5.1 Prodromal phase

In the prodromal period of smallpox, the fever, myalgia and prostration closely resemble influenza. Backache is a very common, although not an invariably present, symptom. The muscle tenderness sometimes affects the abdominal musculature to the extent that appendicitis is suspected and, in fact, in Marsden's series of cases³ this was the most common erroneous hospital admission diagnosis. If the patient is experiencing the haemorrhagic variety of smallpox, the presence of haemorrhage and the abnormal blood picture frequently suggests acute leukaemia or idiopathic thrombocytogenic purpura.

During the brief prodromal period, a definitive diagnosis is difficult, if not impossible. If the diagnosis of smallpox is considered possible, the patient should be appropriately isolated and all necessary measures with respect to vaccination of contacts, isolation, etc., should be promptly instituted.

1.5.2 Early eruptive stage

The rash in the haemorrhagic or flat types develops quite differently from that of the ordinary type and so must be considered separately. The morbilliform, erythematous, superficial rash of the flat form may be mistaken for severe measles, rubella or drug toxicity. In measles, however, the more typical rash should be evident on the chest and back, the temperature should be higher, and respiratory and conjunctival symptoms pronounced. In rubella, the rash appears very rapidly and lymph node enlargement is usually quite evident. Drug rashes, although sometimes centrifugal in distribution and affecting pressure points preferentially, usually evolve more rapidly and the rash is apt to show sharp changes in density. The haemorrhagic smallpox case may not be differentiated from other forms of febrile purpura; however, its abrupt onset with pyrexia and apprehension should distinguish it from acute leukaemia.

In ordinary smallpox, the first few papules may resemble acne or insect bites and, if the smallpox is of a modified type with comparatively few developing lesions, they may be irregularly distributed. The presence of the prodromal fever and myalgia, if present, should point toward smallpox as a diagnosis. The sudden appearance of acne or insect bites in a contact who has not been previously afflicted should also suggest smallpox. Scrapings of the lesions for material for virus isolation may be helpful; frequently, however, little material is present.

Secondary syphilis must also be considered. However, syphilitic lesions are usually soft as opposed to the shotty smallpox lesions, and lack uniformity in size.

1.5.3 Vesicular and pustular stage

In this stage, varicella usually represents the most difficult diagnostic problem. ~~In general, with varicella, there is only a very brief pre-eruptive or no fever of 12, to 24 hours;~~ myalgia and backache are rare; the temperature does not drop abruptly when the rash appears as in the instance of ordinary smallpox. The rash of chickenpox is centripetal in distribution affecting indiscriminately the flexures, such as the axillae, areas which are relatively spared in smallpox. The varicella lesions evolve more rapidly and successive crops of lesions appear over a period of four to five days or more. The lesions themselves are much more superficial, irregular or crenated in shape, variable in size. Smallpox lesions, on the other hand, emerge over a period of one to two days but in a given area are very similar in size. They are round, regular, pearly white and shotty in character. Vaccino-modified cases of smallpox present the most troublesome diagnostic problems since the lesions may emerge over four to five days, evolve rapidly as with chickenpox and may or may not conform to the usual centrifugal distribution. Similarly, irritation of the skin, common in early chickenpox, may also be evident in the vaccino-modified case of smallpox. The highly atypical vaccino-modified smallpox case may not be able to be differentiated from a case of mild varicella without laboratory assistance. Fortunately, however, as previously noted, such cases are rare and they do not appear to transmit the disease with as much facility as the full-blown typical cases of smallpox.

Generalized vaccinia may occasionally pose a difficult diagnostic problem. However, the distribution of lesions tends to follow no orderly gradient centrifugal pattern as with smallpox and in the instance of patients with eczema, the rash will involve areas previously or currently afflicted with this disease. Curiously, the tip of the nose is almost invariably spared. The lesions themselves, however, may not differ from those observed in cases of smallpox. Laboratory assistance may be required for a certain diagnosis.

2. Laboratory diagnosis of smallpox

As described in the section dealing with surveillance, laboratory diagnosis of suspect smallpox cases should be undertaken routinely in areas which have been rendered smallpox-free and in areas where the incidence has reached very low levels. This is to establish with certainty whether or not the cases are indeed smallpox and thus to ensure that the appraisal with respect to the eradication status is accurate. Laboratory facilities presently are very limited. During 1967, WHO will undertake, through training and the development of Regional Diagnostic Centres, to ensure that a laboratory diagnostic service is available at a regional level for less populous countries and at a national level where warranted. Until routine arrangements can be made, the WHO Regional Office should be contacted with respect to the disposition of specimens requiring testing.

Several techniques are available for the presumptive identification of variola virus. The word "presumptive" is used advisedly for only by actual virus isolation is a definitive identification of the virus possible.

In most endemic countries, principal reliance at present will be placed on simpler techniques for laboratory diagnosis such as agar-gel precipitation and virus isolation in chick embryo. Other techniques, such as electron microscopy or immunofluorescence, require expensive equipment, highly skilled personnel and considerable experience and thus will be available in few areas.

2.1 Collection and despatch of specimens

2.1.1 Collection

Material from skin lesions. For microscopic demonstration and isolation of virus, material should be obtained by scraping macules, papules or the base of vesicles with a Hagedorn needle or small scalpel. The scraping should be smeared on clean slides. Five or six lesions should be sampled; gross admixture of blood is undesirable. The slides should be allowed to dry in air and should not be placed in a fixative or in a disinfectant. They should be separated from each other by means of rubber bands or small pieces of cardboard, wrapped in greaseproof paper, and placed in a container for despatch to the laboratory.

Vesicle fluid and pustular fluid. They are best collected in small glass capillary tubes which are put in a screw-capped bottle or other suitable container for despatch. If capillary tubes are not available, the material may be spread thickly on glass slides and allowed to dry in air. In the laboratory, the material on the slides may be washed off in a small volume of saline and used for the detection of antigen and/or for culture.

Blood. If blood is to be used for examination for virus in the first few days of illness, a few millilitres should be collected into citrate. If obtained for antibody studies, the blood should be allowed to clot and the serum then removed.

Scabs. At least six scabs per patient should be collected and placed in a screw-capped bottle for despatch.

2.1.2 Despatch

All the specimens mentioned above and the instruments used for their collection must be regarded as highly infective. It is therefore essential that all specimens and containers should be securely packed in double sealed metal, wooden or strong cardboard containers before being sent to the laboratory.

Specimens may be sent to the laboratory without refrigeration.

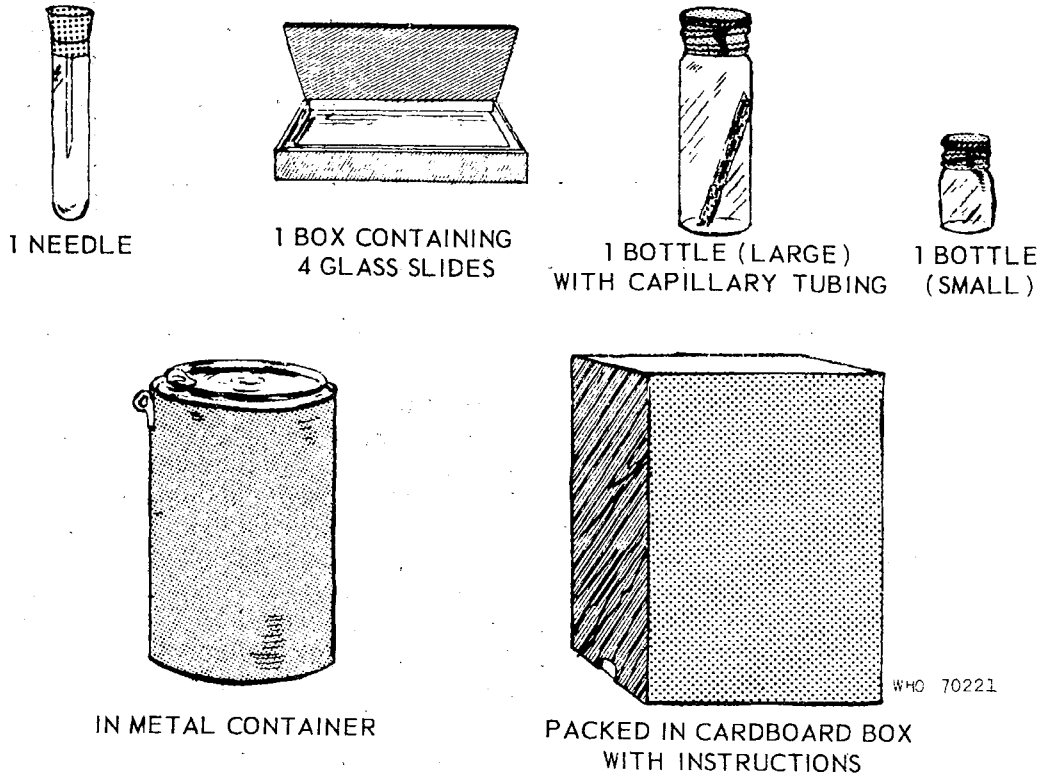
The receiving laboratory should be informed of the estimated time of their arrival. Packages sent through the post should conform to national and international postal requirements.

With all specimens sent to the laboratory, details should be given of the patient's age, name, address, history of contact, history of vaccination, date of onset of illness, and date of appearance of rash.

2.1.3 Kit for specimen collection

A sample kit which may be useful as a standard item for specimen collection is shown below.

SMALLPOX OUTFIT



2.2 Diagnostic methods

A summary table dealing with specimens required and diagnostic tests for variola at different stages of the disease is shown below. This may be helpful for reference when the various methods of diagnosis are described.

Stage of disease		pre-eruption	macular papular	vesicular	pustular	crusting	convalescent	
		Blood	smear	fluid or smear	fluid or smear	crusts	serum	Result in
Virus Isolation		+	+	+	+	+		2-3 days
Agar-gel diffusion			(+)	+	+	+		4-8 hrs.
Complement-fixation				(+)	+	+		18-24 hrs.
Electron microscopy			+	+	+	+		1 hr.
Ordinary microscopy Histological examination			+	+	+			1 hr.
Serological (C.F, HAI) Test for antibody							+	1-3 days

2.2.1 Virus isolation. This is the most reliable and sensitive of all laboratory techniques for the diagnosis of smallpox. It should always be used as a confirmatory test to supplement any other diagnostic method employed. Isolation of virus may be carried out on the chorio-allantoic membrane of 11-13 day chick embryos or in tissue cultures. This technique should give positive results at all stages of the disease, from the appearance of the first macule to the disappearance of all crusts from the patient's skin. In patients with severe, and particularly with fulminating, infections, virus may be isolated from the blood in the first day or two of illness. The buffy coat from the blood is more likely to give a positive result than the whole blood.

The typical appearances produced on the chorio-allantoic membrane within three days will enable a tentative specific diagnosis to be reached by the experienced worker without serological confirmation.

Tissue culture (preferably human or monkey cells) may be used instead of chorio-allantoic membrane for isolation of virus. The presence of virus in the tissue culture may be detected by immunofluorescence or the development of Guarneri bodies in 24 hours, by haemabsorption of fowl cells in 48 hours, or by cytopathogenic effect in two to four days. These time intervals may be shortened when the virus content of the inoculum is high. Experienced workers may be able to identify the specific virus by the character of the inclusion bodies or the pattern of cytopathogenicity.

When confirmation of the identity of a virus isolated on the chorio-allantoic membranes or in tissue culture is required, this may be done by demonstration of specific variola-vaccinial antigen by haemagglutination, complement-fixation or gel-diffusion techniques, using a specific anti-vaccinial serum prepared in the rabbit; or specific neutralization of the virus by immune serum may be determined in tissue culture or on the chorio-allantoic membranes. These tests, however, will not distinguish variola from vaccinia virus. The differential identification can be confirmed by the nature of the lesions on the chorio-allantoic membranes and in tissue culture and by the fact that vaccinia virus will produce demonstrable lesions at an incubator temperature of 39°-40°C while neither kind of variola virus will grow at this temperature.

2.2.2 Agar-gel diffusion precipitation method

In this technique, hyperimmune rabbit serum (against vaccinia virus) is placed in a cup formed in agar gel, mounted on a slide and either vesicular or pustular fluid (or an extract of one or two crusts) is placed in a separate cup; a known positive extract of smallpox or vaccinial material should be placed in a third cup so that the three cups lie at the vertices of an equilateral triangle. The shorter the sides of this triangle the more sensitive the test and the greater the rapidity with which the results appear. As antigen and antibody diffuse towards each other through the agar, a line of whitish precipitate develops where they intermingle in optimal proportions. Lines of precipitation may appear as early as ^{two} ~~three~~ hours after the test is set up but a report should not be issued until it is seen whether the line from the positive control will link with that of the test material or cross it. The latter may happen in cases where the material is pustular. Such specimens ^{may} often give false positive lines of precipitate against rabbit serum. A fourth hole in the agar with normal rabbit serum may help to clarify this point. If the two lines of precipitate join to form a continuous arc, then the test may be read as positive. This can happen within six to eight hours.

Variola virus cannot be distinguished from vaccinia virus by means of this test. In addition, if sufficient material from the lesions has not been obtained, a false negative test may result. *Vesicular fluid & crusts should not be diluted more than 1:5 and preferably should be used undiluted.*

2.2.3 Complement-fixation

The complement-fixation technique is a very sensitive method of detecting smallpox antigen in vesicular or pustular fluid or extracts of crusts or in the blood serum of patients with fulminating infections. This method, however, requires a high level of technical competence. Material should be tested with a hyperimmune rabbit serum and known positive and negative control preparations

should be included with all diagnostic tests. Overnight fixation in the cold gives more satisfactory results than a shorter period of fixation at room temperature or at 37°C (98.6°F). The results should be available within 18 to 24 hours. This technique for detecting antigen is more sensitive than the agar-gel diffusion method, but the results are not so quickly available, a considerable amount of material is required (three to four crusts or three slides with thick smears), and the technique itself is complicated.

2.2.4 Electron microscopy

This method, in the hands of those experienced in this technique, will give highly satisfactory results and enable a presumptive diagnosis to be made within a few hours. This has the advantage over the simple staining of smears in that it may serve to detect typical pox virus particles in pustular fluid and even from crusts in the late stage of the disease. Additionally, varicella and herpes simplex viruses may be identified, if present. It must be emphasized, however, that this method requires considerable experience and skill in use and application of the electron microscope.

2.2.5 Ordinary ~~microscopy~~ histological examination

Smears taken from skin lesions and appropriately stained, fixed and examined microscopically, may be useful in establishing a presumptive diagnosis. The procedure, although comparatively simple from the mechanical standpoint, requires considerable experience for proper interpretation. Additionally, results are most unsatisfactory for pustular lesions. Confirmation by virus isolation must still be undertaken in all instances.

In smallpox lesions, cytoplasmic inclusions (Guarnieri's bodies) may be seen, intranuclear inclusions are uncommon and multinucleated cells are usually absent. In varicella and herpes simplex lesions, intranuclear inclusions in the cells may be found but ~~these~~ elementary bodies are usually scanty, stain poorly and appear smaller; multinucleated cells are usually present. Vaccinia and cowpox demonstrate a similar histological picture to that observed with variola.

Smears from skin lesions should be fixed and stained for virus particles by Gutstein's, Hertzberg's or Gispén's modification of Morosow's technique. If such smears are properly prepared from early cases of smallpox, innumerable virus particles will often be found.

The simplest staining method, that of Gutstein, is described below.

Slides smeared with scrapings are fixed by flooding with methanol for 10 to 30 minutes; alcohol is added as needed to prevent drying. The methanol is washed off with distilled water. A freshly prepared mixture of equal parts of 1% aqueous solution of methyl violet and 2% aqueous solution of sodium bicarbonate is filtered on to the slide. Gentle heat is applied until steam rises and this heating is repeated three or four times during a five-minute period. The stain is then flushed off the slide with distilled or tap water and the slide is blotted dry on filter-paper.

The smear is examined under an oil-immersion lens. A tentative positive report is made only if innumerable elementary bodies are seen. They are of uniform size, about one-quarter that of Staphylococci, uniformly deeply stained and confined to the area of the smear. A smear from a vaccinia lesion has an identical appearance and constitutes an excellent comparison slide.

Virus particles are less numerous in vesicle fluid, and material from pustular lesions is unsatisfactory.

2.2.6 Immunofluorescence

As in the instance of electron microscopy, considerable equipment as well as special reagents and substantial experience are required for application of this method. For diagnostic work, it appears to offer few advantages over electron microscopy. Different groups who have endeavoured to employ this technique have met with varying success. A few laboratories continue to employ this technique while others have abandoned it completely.

2.2.7 Serological methods *Detection of antibody in the post-vaccination serum*

These methods are concerned with the detection of antibody in the patient's serum after the first few days of illness. In these tests either vaccinia or variola can be used as antigen. The examination of a specimen taken during the first few days of illness and one after the first week is desirable to demonstrate a rise in antibody titre. In the interpretation of results, it is important to bear in mind that recent vaccination may induce the formation or increase of antibody in the same manner as smallpox.

Haemagglutination-inhibition. This technique for measuring antibody will often give high titres (over 1:1000) and is technically simpler than the complement-fixation test. Vaccinia haemagglutinin prepared in eggs is the antigen used. Since haemagglutination-inhibiting antibody may persist at low levels for some years after vaccination against smallpox, paired sera should be used, if available. Antibody rise can be demonstrated after the fifth to sixth day of illness.

Complement-fixation. See also 2.2.3. Complement fixation antibodies usually become positive about the seventh or eighth day of illness at serum dilutions up to 1:640. A positive result in a serum dilution of 1/20 or over would usually be significant in a patient not recently vaccinated.

Precipitating antibodies. Most convalescent smallpox sera used undiluted will form lines of precipitate in agar gel against a vaccinia or variola antigen; this is not usually observed in post-vaccination sera.

Neutralization. The serum of patients with suspected smallpox may be tested for its power to neutralize vaccinia or variola virus on the chorio-allantoic membrane or in tissue culture. This test is rather more time consuming than either complement-fixation or haemagglutination-inhibition. Neutralizing antibodies may persist in the serum for many years after smallpox vaccination so that only a very high titre can be considered significant in a single test on a vaccinated individual.

REFERENCES

1. Dixon, C. W. (1962) Smallpox, J. & A. Churchill Ltd., London
2. Rao, A. R. (Personal communication)
3. Marsden, J. P. (1948) A critical review of the clinical features of 13 686 cases of smallpox (variola minor), Bull. Hyg. (Lond.), 23, 735

Other sources

- Gordon, C. W. (1966) Variola minor, Lancet, 1, 1311-1313
- McKenzie, P. J. et al. (1965) Haemorrhagic smallpox, II. Specific bleeding and coagulation studies, Bull. Wld Hlth Org., 33, 773-782
- Rao, A. R. (1964) Haemorrhagic smallpox, a study of 240 cases, J. Indian med. Ass., 43, 224-229
- Ricketts, T. F. & Byles, J. B. (1908) The diagnosis of smallpox, Cassell, London
- Roberts, J. F. et al. (1965) Haemorrhagic smallpox, I. Preliminary haematologic studies, Bull. Wld Hlth Org., 33, 607-613
- World Health Organization, Expert Committee on Smallpox (1964) Wld Hlth Org. techn. Rep. Ser., 283